

Impact of Shoulder Sonography on Clinical Decision Making

Michael V. Friedman, MD, Travis J. Hillen, MD, David V. Holland, MD,
James M. Essenberg, MD, Jennifer L. Demertzis, MD

Objectives—To assess the impact of musculoskeletal shoulder sonography (US) on clinical decision making.

Methods—This Health Insurance Portability and Accountability Act–compliant retrospective study received Institutional Review Board approval with a waiver of informed consent. Consecutive musculoskeletal shoulder US examinations ordered over a 12-month period were retrospectively reviewed. The medical records of each patient were analyzed, recording immediate pre- and post-US treatment plans. Treatment plans were categorized as follows: 1, no further treatment; 2, conservative management/physical therapy; 3, therapeutic injection; 4, surgical intervention; 5, change in diagnosis; and 6, need additional imaging. Data were analyzed by non-parametric statistical methods.

Results—A total of 935 patient examinations met inclusion criteria. Of 935 patients, 591 (63.2%) had a post-US treatment plan that differed from pre-US treatment, showing a statistically significant impact on patient treatment ($P < .001$). In 744 of the 935 examinations (79.6%), the treating physician initially prescribed conservative therapy as a treatment plan; 423 of those 744 patients (56.9%) were subsequently prescribed a more invasive form of treatment. Of the remaining 191 of 935 patients (20.4%) initially treated with invasive treatment, 101 (52.9%) received a change in the treatment plan after the US examinations, with 46 patients (24.1%) relegated to noninvasive treatment. Sonography also played a role in surgical planning, with 25 studies (2.7%) specifically performed to evaluate rotator cuff integrity when deciding between conventional and reverse shoulder arthroplasty.

Conclusions—Musculoskeletal shoulder US has a substantial impact on clinical decision making and patient treatment.

Key Words—clinical management; impact; shoulder; sonography

Received July 8, 2016, from the Washington University School of Medicine, Mallinckrodt Institute of Radiology, St Louis, Missouri USA. Manuscript accepted for publication September 23, 2016.

This was presented in part at the 102nd Scientific Assembly and Annual Meeting of the Radiological Society of North America; November 27–December 2, 2016; Chicago, Illinois.

Address correspondence to Michael V. Friedman, MD, Washington University School of Medicine, Mallinckrodt Institute of Radiology, 510 S Kingshighway Blvd, St Louis, MO 63110 USA.

E-mail: friedmanm@mir.wustl.edu

Abbreviations

MRI, magnetic resonance imaging; PT, physical therapy; US, sonography

doi:10.7863/ultra.16.07013

Shoulder pain is the third most common musculoskeletal presenting symptom after knee and low back pain. Affecting 16% to 26% of the population, shoulder pain is often recurrent and can result in substantial disability.¹ Because many common shoulder disorders present similarly, clinical assessment is difficult.² On the basis of the history and physical examination, including specific orthopedic maneuvers, clinicians may be able to narrow the differential diagnosis for the presenting shoulder symptoms by following an algorithmic approach.³ Radiography, computed tomography, magnetic resonance imaging (MRI), and sonography (US) imaging are validated imaging modalities that can be used to further narrow the differential diagnosis and direct patient care.⁴

Rotator cuff disease is one of the most common causes of shoulder pain.^{5,6} After initial radiographs, MRI has long been the

primary diagnostic imaging modality used in the evaluation of rotator cuff disorders. However, advances in US technology have spurred a diagnostic shift,^{7,8} supported by current literature^{9–14} confirming the accuracy of musculoskeletal US in the evaluation of partial-thickness (sensitivity, 0.84; specificity, 0.89) and full-thickness (sensitivity, 0.96; specificity, 0.93) rotator cuff tears. Sonography has also been shown to have a good correlation with MRI in the assessment of secondary rotator cuff muscular atrophy.^{15,16} Validation of musculoskeletal US as a diagnostic tool, development of affordable portable US equipment, and incentives to reduce health care costs have led to increased use of musculoskeletal US in the evaluation of suspected rotator cuff disease,^{7,8} by both radiologists and other subspecialists.^{17–20} Recognizing this trend, the Society of Radiologists in Ultrasound recently issued a consensus statement of recommended imaging algorithms for the evaluation of rotator cuff disorders and acknowledged the widespread growth of musculoskeletal US as a validated cost-effective diagnostic imaging modality in patients with suspected rotator cuff-induced shoulder pain.²¹ However, to the best of our knowledge, there has been no investigation into the actual diagnostic impact of musculoskeletal shoulder US on the current orthopedic clinical evaluation.

The purpose of this study was to assess the impact of musculoskeletal US of the shoulder on clinical decision making. Our hypothesis was that musculoskeletal shoulder US currently plays a substantial role in daily clinician decision making and patient treatment.

Materials and Methods

This Health Insurance Portability and Accountability Act–compliant retrospective study received Institutional Review Board approval. Informed consent was waived by the review board secondary to the retrospective nature of this analysis.

Study Population

The patient population was selected from the institution's searchable radiology information system database with *Current Procedural Terminology Code* 76881 applied. Musculoskeletal shoulder US is performed as a complete US examination at our institution. A total of 912 patients with 1037 consecutive musculoskeletal shoulder US examinations ordered by 15 different academic orthopedic surgery faculty at our institution over a 12-month

period were retrospectively reviewed. Among these patients, 125 had bilateral examinations, which were managed independently and therefore scored as individual examinations; 102 examinations were excluded from the study: 100 did not have pre- and post-US clinic notes, and 2 were performed for contralateral comparisons. A total of 935 patient examinations had both pre- and post-US clinical evaluations, meeting inclusion criteria for the study.

Imaging

All US examinations were performed with a LOGIQ E9 scanner (GE Healthcare, Milwaukee, WI) using a 6–15-MHz linear array transducer. Harmonic imaging was applied in nearly all cases. Real-time scanning was performed by 10 different academic radiologists (4–30 years of experience), each specifically trained in musculoskeletal US, following a standard accepted protocol and technique.²²

Medical Record Review and Treatment Plan Characterization

Three fellowship-trained musculoskeletal radiologists (M.V.F., T.J.H., and J.L.D.) with 4 to 8 years of experience independently analyzed the electronic medical records and clinic notes of each patient, recording immediate pre- and post-US diagnoses and treatment plans. Treatment plans were assigned a number as follows: 1, no further treatment; 2, conservative management/physical therapy (PT); 3, therapeutic injection; 4, surgical intervention; 5, change in diagnosis/nonshoulder etiology; and 6, need additional imaging.

All pre-US initial treatment plans involved categories 2, 3, and 4. Because categories 2 and 3 were frequently prescribed together, they were analyzed as a distinct treatment plan when grouped accordingly. Category 2 was considered noninvasive conservative management. Categories 3 and 4 (including when categories 2 and 3 were prescribed together) were considered invasive treatment.

Treatment plans were strictly categorized according to a definitive statement of intent by the treating clinician regarding treatment, documentation in the medical record of a pharmacy or PT prescription, and a procedure or surgical note that directly correlated with the clinical encounter in question.

Statistical Analysis

Data were analyzed for changes in clinical management based on US results by nonparametric statistical methods. The significance of treatment plan invasiveness alterations was assessed by a McNemar test performed with MedCalc Statistics for Biomedical Research version 12.6.1.0 software (MedCalc Software, Mariakerke, Belgium). $P < .05$ was considered significant.

Results

Of 935 total patient examinations, 591 (63.2%) had a post-US treatment plan that differed from pre-US treatment (Figure 1), showing a statistically significant impact of shoulder US on the invasiveness of patient treatment ($P < .001$; Table 1). The diagnosis was changed to nonshoulder etiology in 23 patients (2.5%). Twelve patients (1.3%) were referred for additional imaging with MRI to evaluate for intra-articular etiologies.

In 744 of the 935 patient examinations (79.6%), the treating physician initially prescribed conservative therapy as a management plan. After the musculoskeletal shoulder US examinations were obtained for those 744 patients, the specific treatment plan was altered in 490 (65.9%) of those examinations (Table 2); 254 (34.1%) of those patients had no change in treatment; and 42

(5.7%) of those patients who were initially treated conservatively received no further treatment. Categories 2 and 3 (PT/injection), 3 (injection), and 4 (surgery) were viewed as incremental increases in treatment plan invasiveness from category 2 (conservative/PT). On the basis of this assumption, 423 of 744 patients (56.9%) were subsequently prescribed a more invasive form of treatment (272 patients, therapeutic injection; 151 patients, surgery).

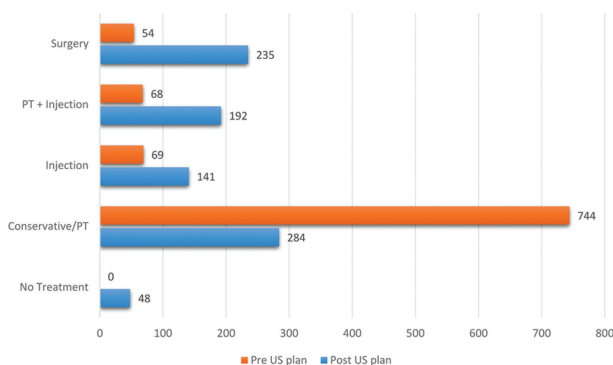
For the remaining 191 of 935 examinations (20.4%), the patients initially underwent invasive treatment; 137 patients were treated with therapeutic injection, and 54 were scheduled for surgery before undergoing a US examination. Of those 191 patients, 101 (52.9%) received a change in the treatment plan after the US examination, with 46 patients (24.1%) relegated to noninvasive treatment (Table 2). Clinical management was altered in 39 patients (20.4%) from nonsurgical to surgical treatment. Nine of the 54 patients (16.7%) originally scheduled for surgery were downgraded to nonsurgical treatment after the US examination.

Sonography also played a role in surgical planning, with 25 of the 935 studies (2.7%) specifically performed to evaluate rotator cuff integrity and muscle atrophy when deciding between conventional and reverse shoulder arthroplasty.

Table 1. Change in Treatment Plan Invasiveness After the US Examination

Pre-US Plan	Post-US Plan	
	Noninvasive (–)	Invasive (+)
Noninvasive (–)	321	423
Invasive (+)	145	46

Figure 1. Pre- and post-shoulder US treatment plans.



Discussion

Propelled by technological advancements, low-cost capital investment, and emphasis on cost-conscious medical care, there has been remarkable growth in the use of musculoskeletal shoulder US in recent years.⁷ Dynamic, real-time US imaging has been shown to be effective in the evaluation of both rotator cuff and non-rotator cuff shoulder disorders.^{23,24} The diagnostic accuracy of musculoskeletal shoulder US and comparativeness with MRI in the evaluation of rotator cuff disease has been validated.^{9,11–14,21} The impact of musculoskeletal US has been examined in the setting of rheumatic disease.^{25,26} However, to our knowledge, there has been no investigation into the actual diagnostic impact of musculoskeletal shoulder US on the current orthopedic clinical evaluation. Impact studies are important for investigating the clinical relevance of a particular diagnostic test. Although it is accepted that musculoskeletal shoulder US provides valid diagnostic information, how those data influence a

clinician's diagnostic algorithm and ultimately their therapeutic decisions should be assessed. The results of this study document the considerable impact of musculoskeletal shoulder US on clinical decision making. In review of consecutive US examinations performed over a 12-month period at a large academic center, musculoskeletal shoulder US had a significant impact on the invasiveness of patient treatment, with 63.2% (591 of 935) of examinations resulting in a change from pre-US-prescribed treatment.

In nearly four-fifths (79.6% [744 of 935]) of the examinations performed, patients were initially treated conservatively with a combination of rest, ice, PT and nonsteroidal medication. This approach to patient treatment is supported by recent studies showing rotator cuff-related symptom relief with noninvasive treatment.^{27–29} However, after the diagnostic shoulder US examination was performed, 56.9% (423 of 744) of those patients were restratified to a more invasive treatment plan including an injection or surgery. This finding supports our hypothesis that clinicians are increasingly accepting and reliant on musculoskeletal shoulder US as an imaging modality in the evaluation of suspected rotator cuff disease, opting to withhold invasive treatment until a diagnosis is confirmed.

In the remaining 20.4% (191 of 935) of examinations, the ordering clinician opted for invasive treatment before the US examination, including therapeutic injections and scheduled surgery. In both of these clinical settings, musculoskeletal shoulder US also resulted in a substantial impact, as 52.9% (101 of 191) of patient examinations had a change in the treatment plan after the US examination was performed. Forty-six of those patients with initial invasive treatment plans were downgraded to noninvasive treatment after the US examination.

In the current medical environment, rotator cuff surgery is rarely performed without diagnostic imaging.

The history and physical examination by experienced providers can result in a confident diagnosis, allowing for preemptive surgical scheduling.³ However, diagnostic imaging affects presurgical planning and patient expectations regarding the complexity of the repair, secondary interventions that may be required, anticipated functional outcomes, and whether surgical intervention is even necessary.^{30–32} A recent study evaluated the cost-effectiveness of preoperative imaging and found that although preoperative costs are substantial, they represent a fraction of the total cost of surgical treatment.³³ Furthermore, it was suggested that other diagnostic modalities should be used, reserving MRI for patients with inconclusive results.³³ In our study, 5.8% (54 of 935) of patients were scheduled for surgery at the initial clinical visit before undergoing a US examination. Of those 54 patients, 45 (83.3%) proceeded to surgical interventions. The remaining 9 patients (16.7%) canceled surgery on the basis of the US results and pursued revised less-invasive treatment plans: no treatment (1 patient), PT (4 patients), therapeutic injection (2 patients), and referral for cervical radiculopathy (2 patients). Conversely, 20.3% (190 of 935) of the total patient examinations were changed from nonsurgical to surgical treatment after the US examination.

Finally, the use of musculoskeletal shoulder US in the setting of preoperative arthroplasty planning was an interesting, if not unexpected, finding of this study. Conventional total shoulder arthroplasty relies on a functioning rotator cuff to recreate anatomic stability and function. Several studies have shown unsatisfactory outcomes, with asymmetric liner wear and early failure of conventional arthroplasty placement in the setting of massive cuff tears or rotator cuff arthropathy.^{30,31} These findings led to the development of reverse total shoulder arthroplasty, providing semiconstrained stability in the setting of rotator cuff dysfunction and prompting surgeons to evaluate rotator cuff integrity

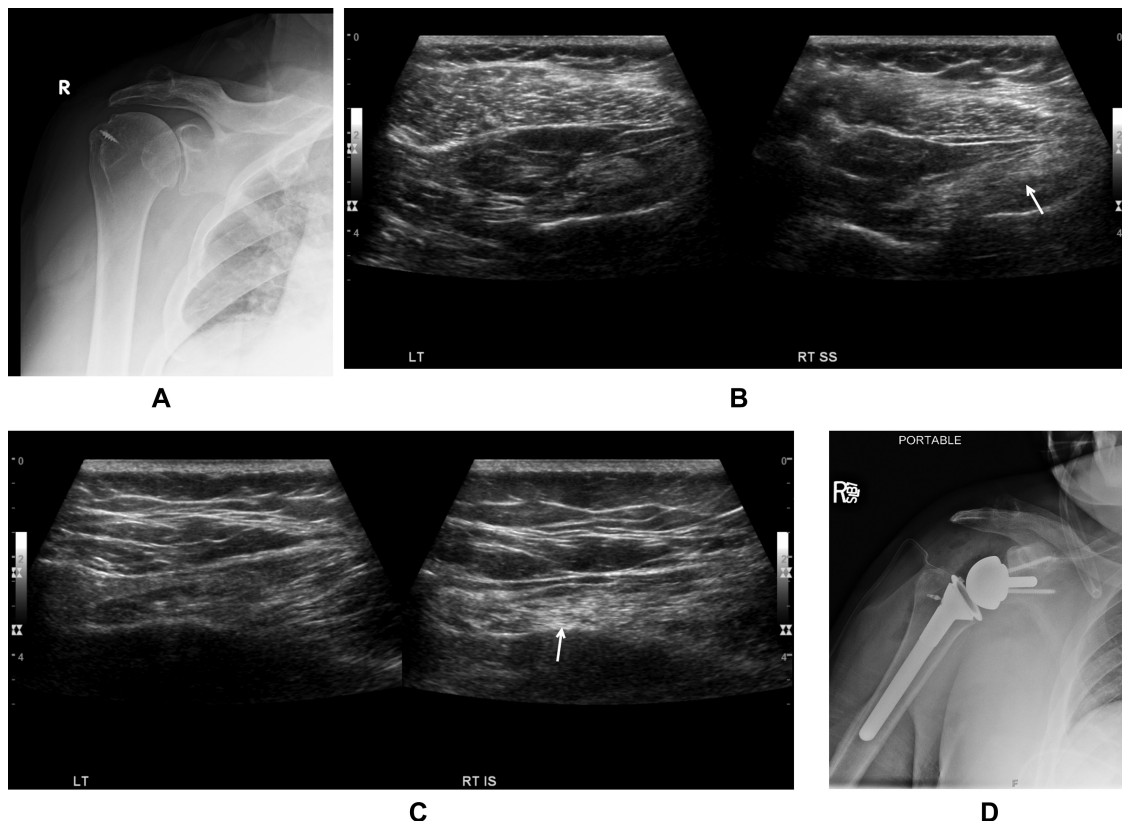
Table 2. Pre- and Post-US Diagnostic Plans for Patients

	Post-US Plan						
Pre-US Plan (935)	No Treatment	Conservative/ PT	Injection	PT + Injection	Surgery	Change in Diagnosis	Additional Imaging
Conservative/PT (744)	42	254	101	171	151	18	7
Injection (69)	4	9	27	3	21	2	3
PT + injection (68)	1	17	11	18	18	2	1
Surgery (54)	1	4	2	0	45	1	1

before prosthetic placement. In addition to cuff tears, rotator cuff muscle fatty (chronic) atrophy is an important prognostic factor in functional rotator cuff repair outcomes. Specifically, the likelihood of recurrent failure after repair is greater in patients who have preoperative chronic muscle atrophy of greater than grade 1 according to the scale of Goutallier et al.³² Magnetic resonance imaging is commonly considered the reference standard for evaluating chronic muscle atrophy; however, recent studies have shown a good correlation between US and MRI in the evaluation of rotator cuff muscle fatty infiltration.^{15,34} In our study, 2.7% (25 of 935) of musculoskeletal shoulder US examinations were ordered preoperatively to specifically assess rotator cuff integrity and chronic muscle atrophy to aid the surgeon in deciding between conventional and reverse ball-in-socket shoulder arthroplasty (Figure 2).

There were several limitations to our study. First, because no assumptions about treatment intent were made during the chart review, our treatment plan analysis was limited by the quality of the physicians' documentation. This potential limitation could be addressed in a prospective trial including participating treating clinicians as well as evaluating clinician confidence in pre- and post-US diagnosis. Second, this study used the treatment algorithms of 15 different orthopedic faculty at our institution. This approach offers insight into a broad spectrum of ordering physicians' patterns within an academic department; however, some physicians use musculoskeletal US more readily than others, and the results may have been influenced by their specific ordering and treatment methods. Last, extended patient follow-up was not evaluated for clinically recurrent symptoms or treatment responses.

Figure 2. Images from a 60-year-old man with end-stage shoulder pain. A US examination was performed to evaluate rotator cuff tendon and muscle integrity in deciding between traditional and reverse ball-in-socket arthroplasties. **A**, Shoulder radiograph showing prior rotator cuff repair with moderate glenohumeral osteoarthritis. **B**, Sonograms showing asymmetric atrophy and increased echogenicity involving the right supraspinatus muscle (SS; arrow), consistent with moderate chronic fatty infiltration. The repair was intact (not shown). **C**, Sonograms showing severe chronic fatty atrophy of the right infraspinatus (IS; arrow). **D**, Shoulder radiograph showing interval reverse ball-in-socket arthroplasty placement, chosen by the surgeon secondary to chronic cuff fatty atrophy.



In conclusion, musculoskeletal shoulder US is an established validated diagnostic imaging modality for the evaluation of clinically suspected rotator cuff disorders. In concordance with recent increased use, this study finds that musculoskeletal shoulder US has a substantial impact on patient treatment and the decision making of clinicians.

References

1. Urwin M, Symmons D, Allison T, et al. Estimating the burden of musculoskeletal disorders in the community: the comparative prevalence of symptoms at different anatomical sites, and the relation to social deprivation. *Ann Rheum Dis* 1998; 57:649–655.
2. Mitchell C, Adebajo A, Hay E, Carr A. Shoulder pain: diagnosis and management in primary care. *Br Med J* 2005; 331:1124–1128.
3. Slaughter AJ, Reynolds KA, Jambhekar K, David RM, Hasan SA, Pandey T. Clinical orthopedic examination findings in the upper extremity: correlation with imaging studies and diagnostic efficacy. *Radiographics* 2014; 34:e24–e40.
4. Wise JN, Daffner RH, Weissman BN, et al. ACR Appropriateness Criteria on acute shoulder pain. *J Am Coll Radiol* 2011; 8:602–609.
5. Shanahan EM, Sladek R. Shoulder pain at the workplace. *Best Pract Res Clin Rheumatol* 2011; 25:59–68.
6. Milgrom C, Schaffler M, Gilbert S, van Holsbeeck M. Rotator-cuff changes in asymptomatic adults: the effect of age, hand dominance and gender. *J Bone Joint Surg Br* 1995; 77:296–298.
7. Jacobson JA. Musculoskeletal ultrasound: focused impact on MRI. *AJR Am J Roentgenol* 2009; 193:619–627.
8. McNally EG. The development and clinical applications of musculoskeletal ultrasound. *Skeletal Radiol* 2011; 40:1223–1231.
9. Smith TO, Back T, Toms AP, Hing CB. Diagnostic accuracy of ultrasound for rotator cuff tears in adults: a systematic review and meta-analysis. *Clin Radiol* 2011; 66:1036–1048.
10. Teefey SA, Hasan SA, Middleton WD, Patel M, Wright RW, Yamaguchi K. Ultrasonography of the rotator cuff: a comparison of ultrasonographic and arthroscopic findings in one hundred consecutive cases. *J Bone Joint Surg Am* 2000; 82:498–504.
11. Teefey SA, Rubin DA, Middleton WD, Hildebolt CF, Leibold RA, Yamaguchi K. Detection and quantification of rotator cuff tears: comparison of ultrasonographic, magnetic resonance imaging, and arthroscopic findings in seventy-one consecutive cases. *J Bone Joint Surg Am* 2004; 86:708–716.
12. Vlychou M, Dailiana Z, Fotiadou A, Papanagiotou M, Fezoulidis IV, Malizos K. Symptomatic partial rotator cuff tears: diagnostic performance of ultrasound and magnetic resonance imaging with surgical correlation. *Acta Radiol* 2009; 50:101–105.
13. de Jesus JO, Parker L, Frangos AJ, Nazarian LN. Accuracy of MRI, MR arthrography, and ultrasound in the diagnosis of rotator cuff tears: a meta-analysis. *AJR Am J Roentgenol* 2009; 192:1701–1707.
14. Roy JS, Braën C, Leblond J, et al. Diagnostic accuracy of ultrasonography, MRI and MR arthrography in the characterisation of rotator cuff disorders: a systematic review and meta-analysis. *Br J Sports Med* 2015; 49:1316–1328.
15. Khoury V, Cardinal E, Brassard P. Atrophy and fatty infiltration of the supraspinatus muscle: sonography versus MRI. *AJR Am J Roentgenol* 2008; 190:1105–1111.
16. Kim HM, Dahiya N, Teefey SA, Keener JD, Galatz LM, Yamaguchi K. Relationship of tear size and location to fatty degeneration of the rotator cuff. *J Bone Joint Surg Am* 2010; 92:829–839.
17. Moosmayer S, Smith HJ. Diagnostic ultrasound of the shoulder: a method for experts only? Results from an orthopedic surgeon with relative inexpensive compared to operative findings. *Acta Orthop* 2005; 76:503–508.
18. Murphy RJ, Daines MT, Carr AJ, Rees JL. An independent learning method for orthopaedic surgeons performing shoulder ultrasound to identify full-thickness tears of the rotator cuff. *J Bone Joint Surg Am* 2013; 95:266–272.
19. Cannella AC, Kissin EY, Torralba KD, Higgs JB, Kaeley GS. Evolution of musculoskeletal ultrasound in the United States: implementation and practice in rheumatology. *Arthritis Care Res* 2014; 66:7–13.
20. Henderson REA, Walker BF, Young KJ. The accuracy of diagnostic ultrasound imaging for musculoskeletal soft tissue pathology of the extremities: a comprehensive review of the literature. *Chiropr Man Ther* 2015; 23:31.
21. Nazarian LN, Jacobson JA, Benson CB, et al. Imaging algorithms for evaluating suspected rotator cuff disease: Society of Radiologists in Ultrasound consensus conference statement. *Radiology* 2013; 267:589–595.
22. Jacobson JA. Shoulder US: anatomy, technique, and scanning pitfalls. *Radiology* 2011; 260:6–16.
23. Papatheodorou A, Ellinas P, Takis F, Tsanis A, Maris I, Batakis N. US of the shoulder: rotator cuff and non-rotator cuff disorders. *Radiographics* 2006; 26:e23.
24. Martinoli C, Bianchi S, Prato N, et al. US of the shoulder: non-rotator cuff disorders. *Radiographics* 2003; 23:381–401.
25. Naranjo A, Jiménez-Núñez FG, Medina-Luezas J, et al. Impact of the use of MSK US by rheumatologists in patients with shoulder and hand complaints compared with traditional clinical care. *Clin Exp Rheumatol* 2012; 30:768–771.
26. Micu MC, Alcalde M, Sáenz JI, et al. Impact of musculoskeletal ultrasound in an outpatient rheumatology clinic. *Arthritis Care Res* 2013; 65:615–612.
27. Safran O, Schroeder J, Bloom R, Weil Y, Milgrom C. Natural history of nonoperatively treated symptomatic rotator cuff tears in patients 60 years old or younger. *Am J Sports Med* 2011; 39:710–714.
28. Baydar M, Akalin E, El O, et al. The efficacy of conservative treatment in patients with full-thickness rotator cuff tears. *Rheumatol Int* 2009; 29:623–628.

29. Beaudreuil J, Bardin T, Orcel P, Goutallier D. Natural history or outcome with conservative treatment of degenerative rotator cuff tears. *Joint Bone Spine* 2007; 74:527–529.
30. Franklin JL, Barrett WP, Jackins SE, Matsen FA. Glenoid loosening in total shoulder arthroplasty: association with rotator cuff deficiency. *J Arthroplasty* 1988; 3:39–46.
31. Neer CS II, Craig EV, Fukuda H. Cuff-tear arthropathy. *J Bone Joint Surg Am* 1983; 65:1232–1244.
32. Goutallier D, Postel JM, Gleyze P, Leguilloux P, Van Driessche S. Influence of cuff muscle fatty degeneration on anatomic and functional outcomes after simple suture of full-thickness tears. *J Shoulder Elbow Surg* 2003; 12:550–554.
33. Yerasosian MG, Terrell RD, Wang JC, McAllister DR, Petrigliano FA. The costs associated with the evaluation of rotator cuff tears before surgical repair. *J Shoulder Elbow Surg* 2013; 22:1662–1666.
34. Kavanagh EC, Koulouris G, Parker L, et al. Does extended-field-of-view sonography improve interrater reliability for the detection of rotator cuff muscle atrophy? *AJR Am J Roentgenol* 2008; 190:27–31.